

Proton Irradiation of Choroidal Neovascular Membrane associated with Age-Related Macular Degeneration

A phase III clinical trial at IUCF
1997 - 2000

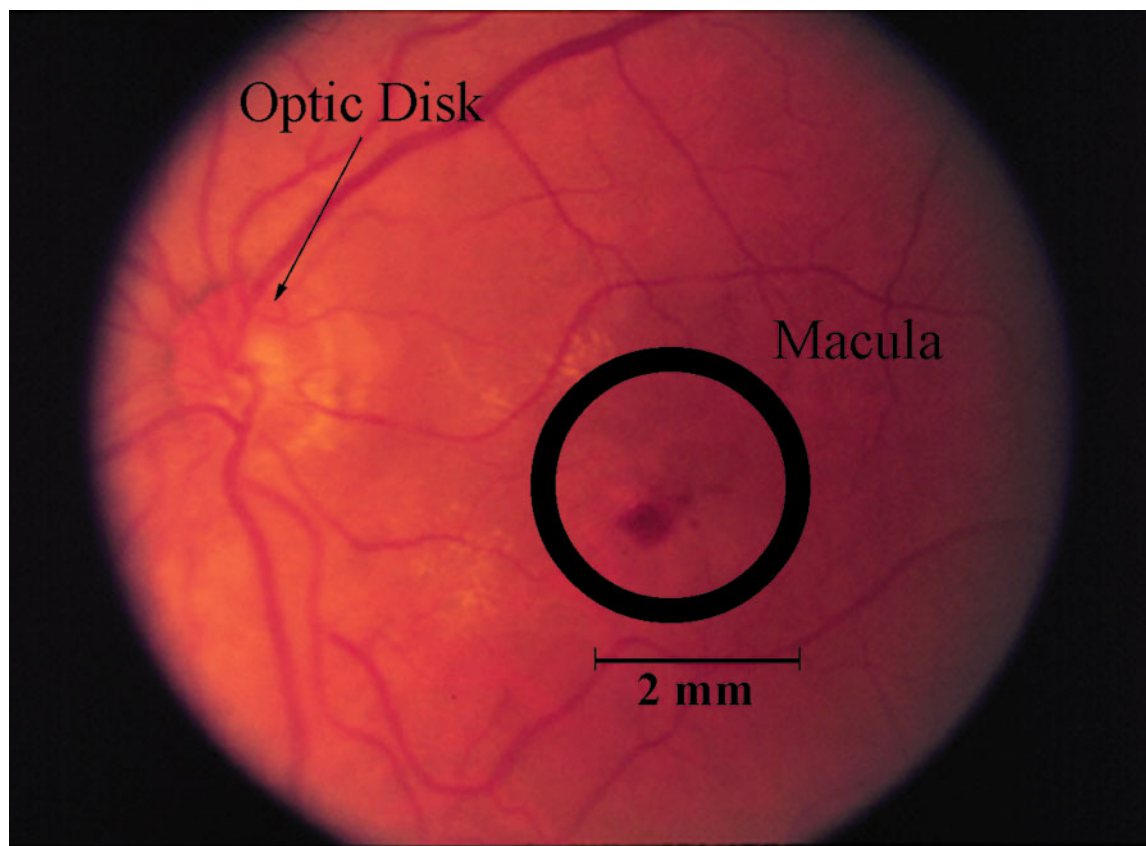
Biology of CNVM

- The retina is the neurological tissue of the eye
- Behind the retina is Bruch's Membrane
- Behind Bruch's Membrane are capillaries
- In wet AMD, the vascular structures invade beyond the Membrane
- Swelling obscures the vision
- Scarring obstructs the vision

Biology of CNVM

- There are 2 types of AMD
 - Dry
 - Wet
- There are 3 types of wet AMD:
 - Classic
 - Occult
 - Mixed
- There is no successful treatment for AMD
- There is no animal model for AMD
- It appears that there is an inflammatory component
- Radiation selectively affects vascular tissue at relative low doses.

Location of the Target and Optic Disk



Clinical Trial Protocol

- Rationale: Beaver Dam Study
 - 15 % 55-64 yr old - 37% 75 + yr old
 - 20% 65-74 yr old
- Hypothesis - Radiation will arrest neovascular growth
- 37 of 200 required were enrolled in study
- Average age at enrollment = 71.1
- Best corrected vision = 20/40, native = 20/400
- Onset of disease w/in 6 months of enrollment
- 16 Gy in 2 fractions
- Followed patient at 3 mo. intervals for 2 yrs.

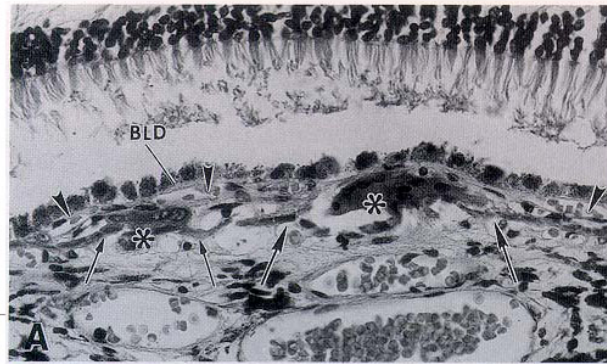
Project Personnel - Investigators

- Tom Cuilla
- Ron Danis
- Newell Pugh
- John Cameron
- Chuck Bloch
- Jim Morphis
- Sarita Soni
- Vic Malinovsky
- Steve Hitzeman
- S. Chung

Project Personnel - IUCF

- Quality Assurance
- Project Manager
- Project Coordinator
- System Manager
- Software Programmer
- Electronics
- Charlie Nelson
- Chuck Bloch
- Moira Wedekind (DH)
- John Collins
- John Collins
- John Callahan

Radiation Biology of the CNVM



Coroidal Neovascular Membrane associated with Age-Related Macular Degeneration



MOUSE

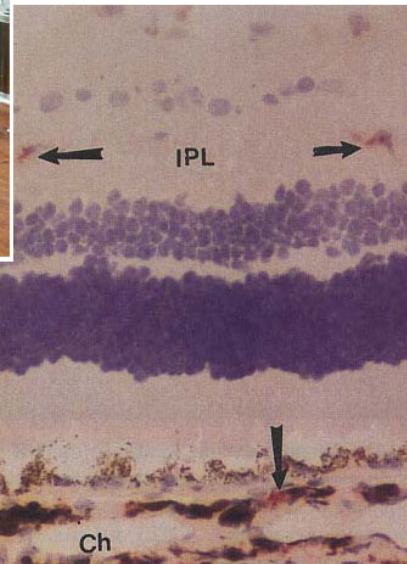



Photo-ablation



Proton Therapy Cave Before AMD Renovation



Clinic Construction in the Low Bay



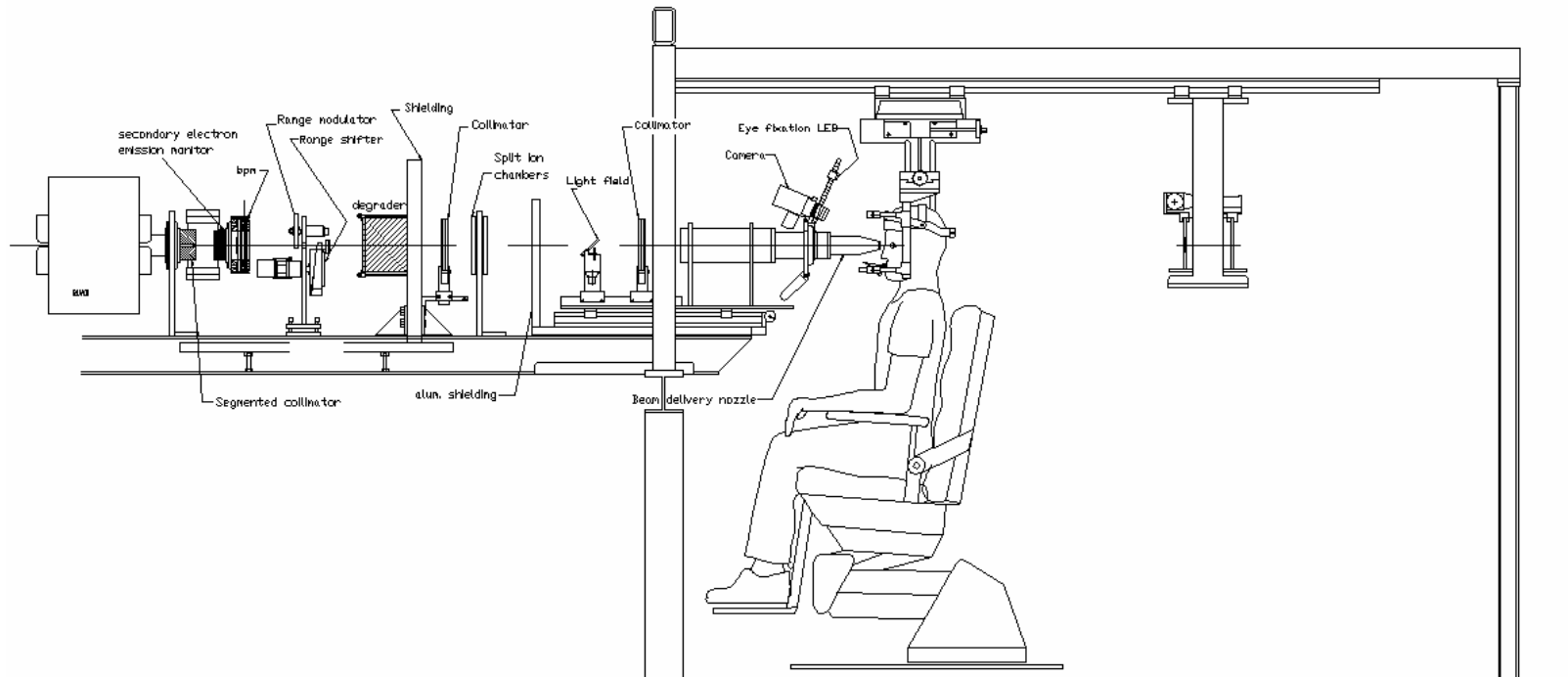
The Eye Treatment Room at IUCF



Two Points of View



The Eye Line




The Eye Line



Aligning the Patient

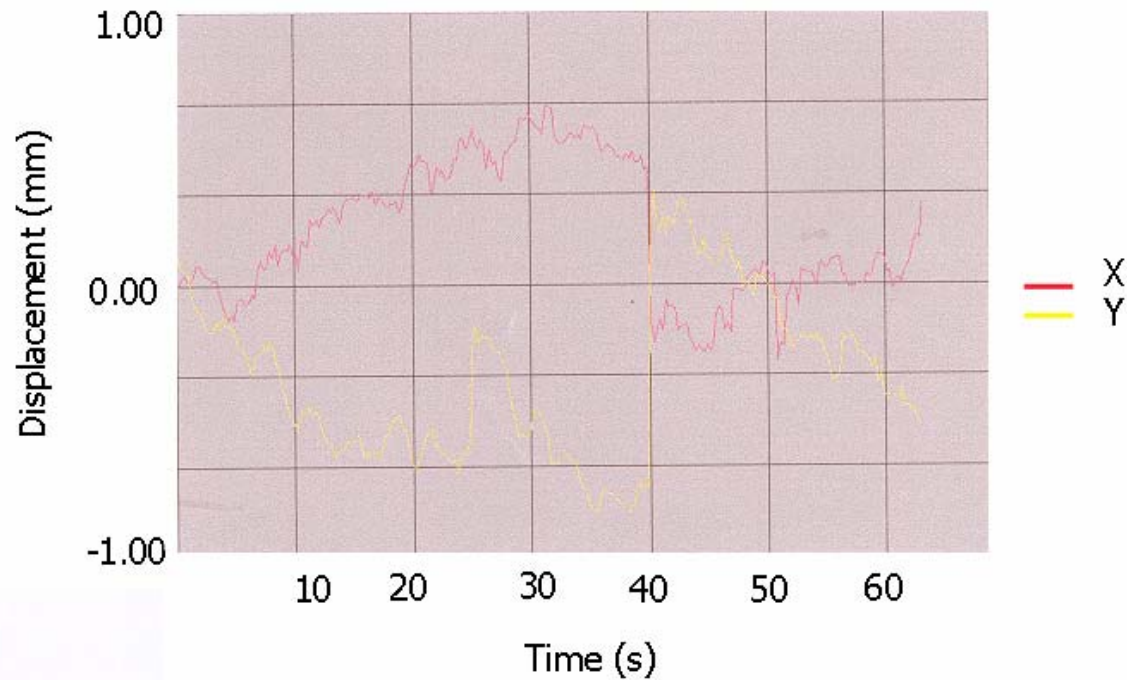


The Head Restraint Device

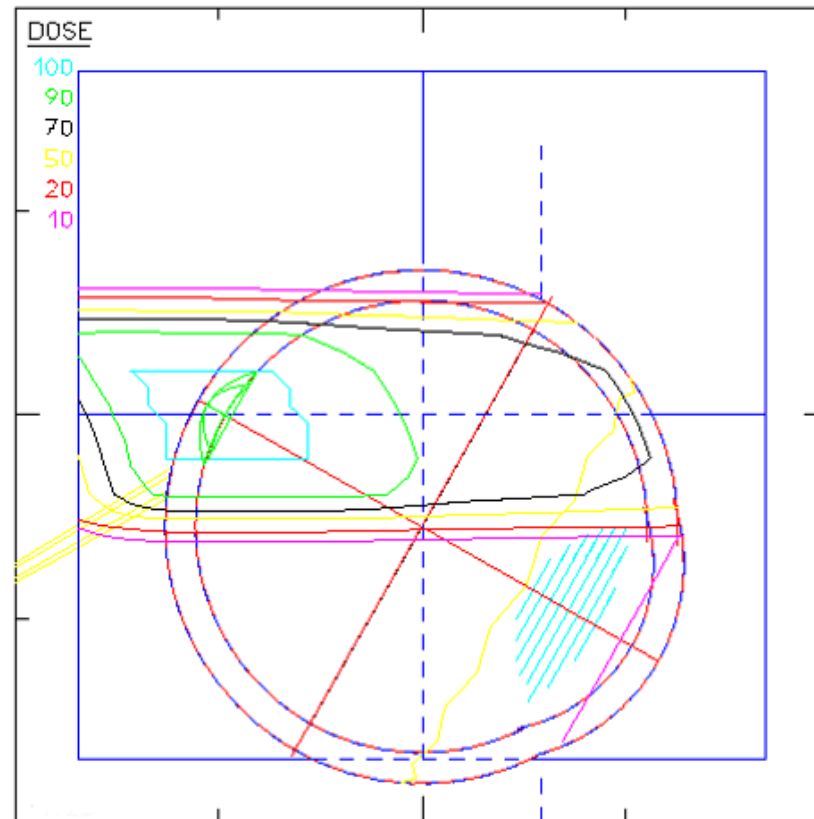


Pupil Displacement During Treatment

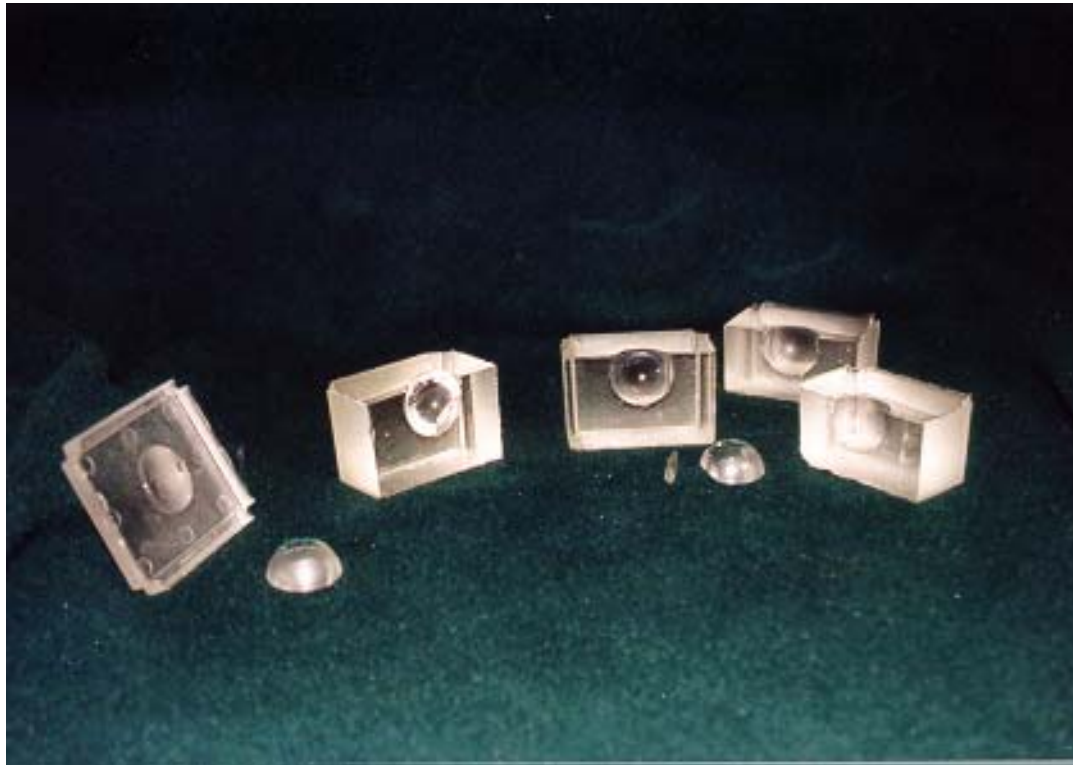
Displacement vs. Time



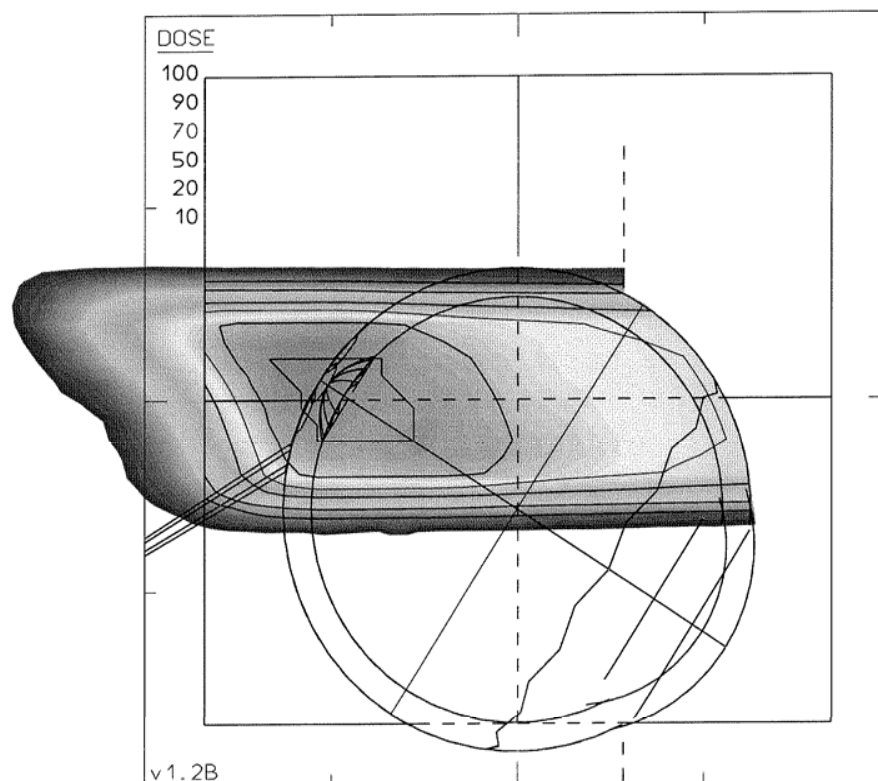
A Typical EYEPLAN Generated Treatment Plan



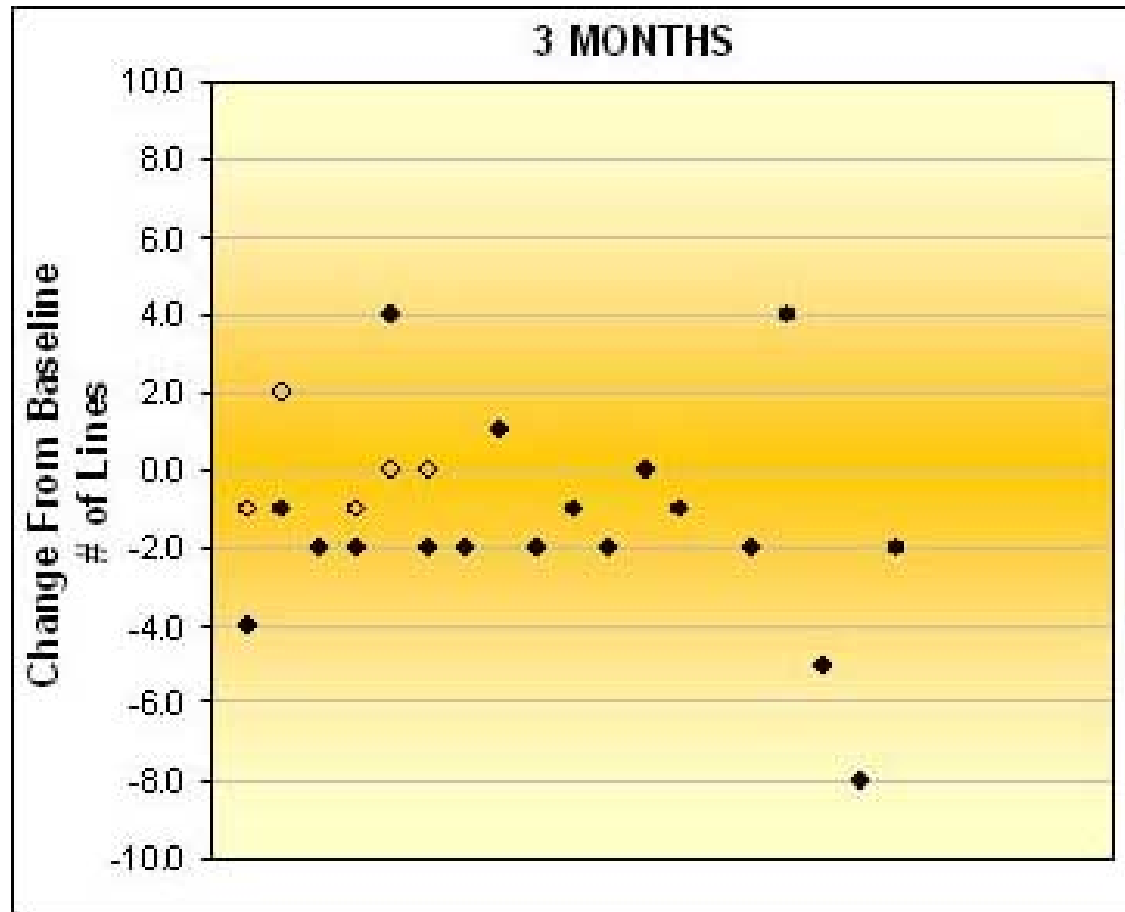
Eye Phantom



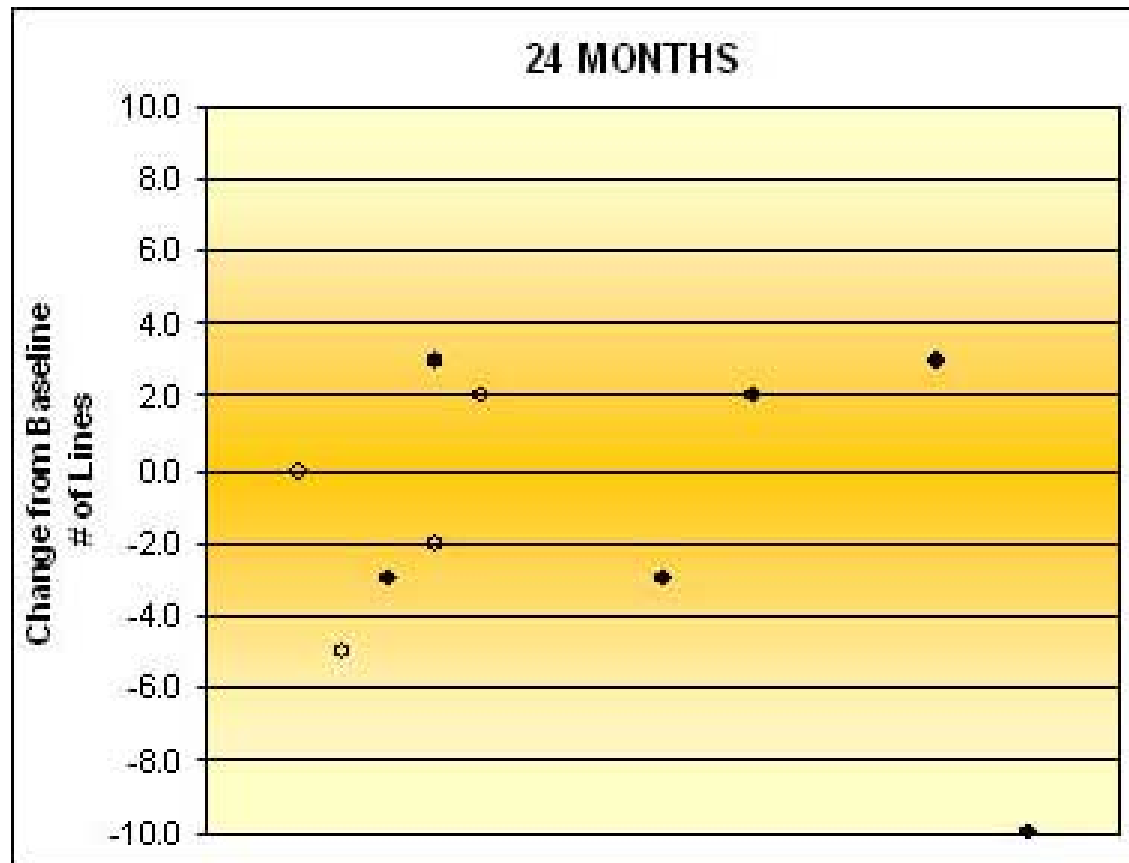
Overlay of EYEPLAN with Digitized Film Image



Change in Vision at 3 Months

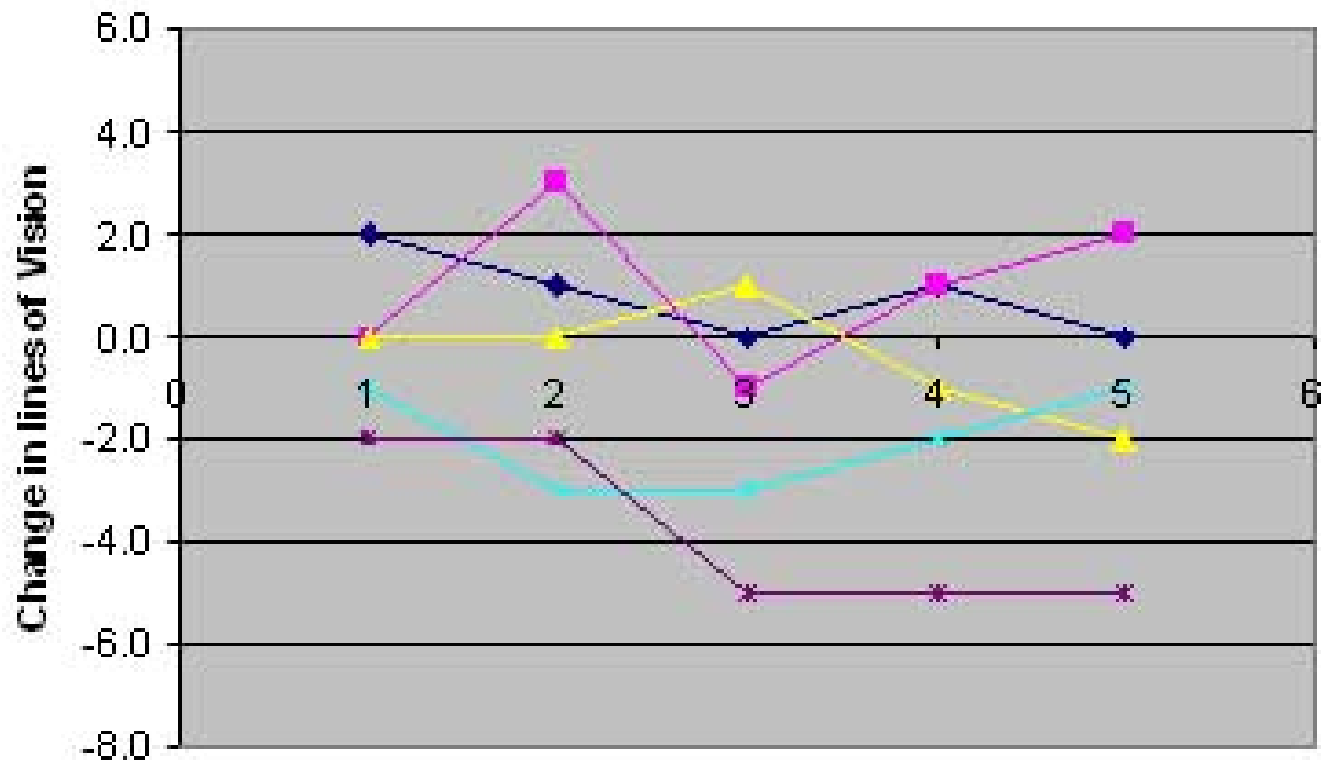


Change in Vision at 24 Months



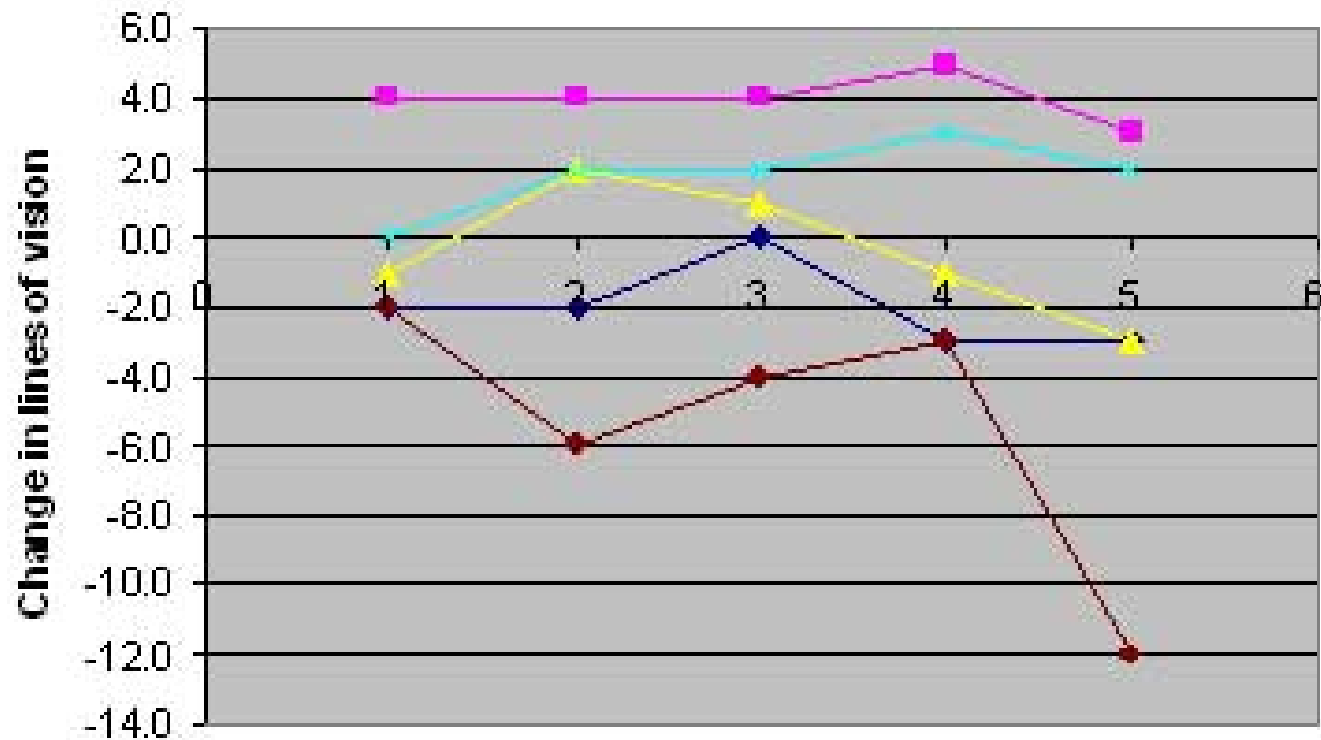
Individual Responses to Treatment

Sham progression



Individual Responses to Treatment

Treated progression



An Ignominious End

